



**PATIENT**

Nugget Mercier

**PRESENTING CLINICAL SIGNS**

History: Grade III/VI heart murmur. No clinical signs. Needs dental cleaning with anesthesia.

**SPECIES**

Feline

**ECHOCARDIOGRAM FINDINGS**

2D, m-mode, color flow and Doppler imaging is available.

**Left ventricle:** The LV diameter is normal with adequate myocardial function. The LV wall thicknesses are asymmetric with mild septal thickening with regions of irregularity. There is a mildly hyperechoic endocardium consistent with fibrosis. The papillary muscles are mildly hypertrophied and hyperechoic. The endocardium appears mildly remodeled.

**BREED**

DSH

**Left atrium:** The left atrium is normal. No smoke or thrombi seen.

**SEX**

Male Neutered

**Mitral valve:** The MV leaflets appears normal. Systolic anterior motion is seen on 2D and color flow imaging. Moderate eccentric MR.

**Aortic valve/Aorta:** The aortic valve is normal in morphology and mobility. Moderately elevated aortic outflow velocity with a dynamic profile. No aortic insufficiency.

**AGE**

9 years

**Right ventricle:** Normal right ventricular diameter and morphology indicating no overt evidence of pulmonary arterial hypertension.

**Right atrium:** The right atrium is normal in dimension.

**Tricuspid valve:** The tricuspid valve appears normal with no tricuspid regurgitation.

**Pulmonary valve/Pulmonary artery:** The pulmonic valve is normal in morphology and mobility. No pulmonic insufficiency. Normal RVOT velocity; laminar flow.

**WEIGHT**

14lbs

**Pericardium/other:** No pericardial or pleural effusion noted. No obvious cardiac masses.

**Heart rhythm:** ECG reveals a sinus rhythm with an average HR of 220bpm.

**INTERPRETED BY**

Maggie Machen  
Lamy, DVM  
DACVIM (Cardiology)

**2-Dimensional Measurements**

Ao diam (cm)	1.0
LA diam (cm)	1.3
LA:Ao (Swe)	1.3
IVS thickness (cm)	0.61
LVID diastole (cm)	1.6
PW thickness (cm)	0.51
LVID systole (cm)	0.6
FS (%)	64

**Doppler Measurements**

PV Vmax (m/s)	0.86
AoV Vmax (m/s)	3.5
MR Vmax (m/s)	NA
TR Vmax (m/s)	NA
TR PG (mmHg)	NA

**IMAGING**

**PERFORMED BY**

Pamela Harrigan,  
RDMS

**INTERPRETATION OF THE FINDINGS**

The diagnosis and cause of the murmur is hypertrophic obstructive cardiomyopathy. This indicates some degree of LV thickening (mild in this case) with a dynamic LVOT obstruction (SAM). The degree of disease appears mild with mild LVH and no left atrial enlargement, indicating the risk for spontaneous CHF and/or a thrombotic event is currently low. No additional issues are identified.

**HOSPITAL NAME**

Wignall Animal  
Hospital

**REFERRING VET**

Dr. Cramb

While no medications have been shown to definitively alter long term outcome at this stage of disease, atenolol is often initiated to decrease the outflow obstruction. Given the mild nature of the findings and lack of a severe obstruction, this is not yet indicated.

**INVOICE**

25717

Prognosis is guarded given the highly variable nature of feline cardiomyopathy.

**DATE**

8/11/22



**PATIENT**

Nugget Mercier

**SPECIES**

Feline

**BREED**

DSH

**SEX**

Male Neutered

**AGE**

9 years

**WEIGHT**

14lbs

**INTERPRETED BY**

Maggie Machen  
 Lamy, DVM  
 DACVIM (Cardiology)

**IMAGING PERFORMED BY**

Pamela Harrigan,  
 RDCS

**HOSPITAL NAME**

Wignall Animal  
 Hospital

**REFERRING VET**

Dr. Cramb

**INVOICE**

25717

**DATE**

8/11/22

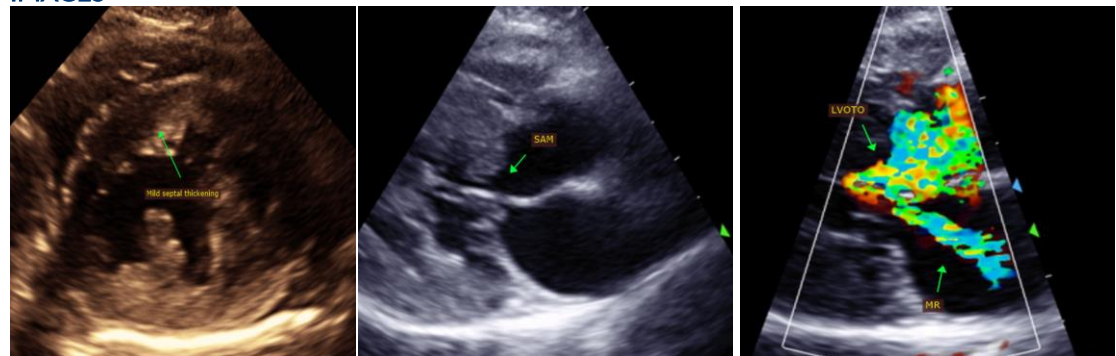
**RECOMMENDATIONS**

- If elected, institute Atenolol 25mg tablets; Give ¼ tab once daily. Recheck heart rate in 1-2 weeks with target stressed rate of 140-160bpm 12-24 hours post-administration. Increase as needed until target reached.
- Anesthetic risk is considered mild, however judicious IV fluid rates are advised to avoid fluid overload. Additionally, drugs that stimulate heart rate should be avoided unless clinically necessary (glycopyrrolate, atropine). Avoid vasodilators as this may worsen the obstruction. A reasonable protocol includes opioid/benzodiazepine premedication, propofol induction, isoflurane maintenance. Additionally, steroids should be used with caution on older cats, as even a 'normal' geriatric heart can develop evidence of intolerance and fluid retention.
- Monitor for any clinical evidence of cardiac compromise, including respiratory changes and/or signs of a blood clot event (paralysis, neurologic changes, etc.).

**PLAN**

- Recommend recheck echocardiogram in 6 months to assess rate of progression, sooner if any issues arise in the interim.

**IMAGES**



The information and recommendations provided are based on the images presented by the referring veterinarian. No evaluation can be communicated regarding pathology that was not visible in the image/video clips provided.

Thank you for this referral. This report was generated using transcription software, and minor dictation errors may be present. If the clinical or image interpretation does not parallel your findings or if I can be of any further assistance, please contact me.

**Maggie Machen Lamy, DVM**  
 Diplomate of the American College of Veterinary Internal Medicine (Cardiology)  
 info@sonopath.com